

The Walleectomy: Embezzlement in the Dental Office

The Kentucky Meeting
Kentucky Dental Association

Presented by:

Pat Little, DDS, FAGD, CFE

**The Walleectomy:
Embezzlement in the Dental Office**

**The Kentucky Meeting
Kentucky Dental Association**

Presented by:
Pat Little, DDS, FAGD, CFE

Disclosure

Prosperident

- Senior Fraud Examiner
- Independent Contractor

Dental Risk Concepts, LLC

- Founder, CEO

Is the Road Really Blocked?


A photograph of a paved road that is completely blocked by several large, light-colored boulders. The background shows trees and a hillside.

What Leads to Embezzlement

Motivation

Rationalization


Opportunity

A photograph of a US one-dollar bill tied in the middle with a white rope, forming a knot. The bill is held taut by the rope.

Types of Embezzlers

Greedy
Self-entitled
Sociopathic


Needy
Start off honest
Usually high seniority

A photograph of a stack of several US one-hundred dollar bills, fanned out slightly.

Types of Embezzlement


Expense

Revenue

A photograph of a hand holding a large fan of US one-hundred dollar bills.

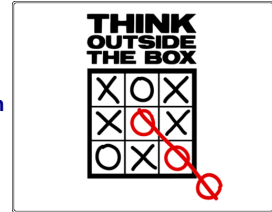
Weaknesses of Internal Controls

- Impossible to “plug” all holes
- Well-known by the employee
- Adaptive to new controls



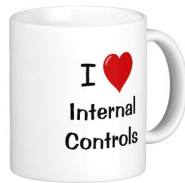Something To Think About

- Motivation trumps controls
- Quick and plausible explanation
- False sense of security



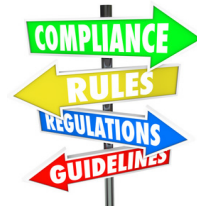Internal Controls – Good for Anything?

- Detect innocent mistakes
- Prevention *in that area*
- Enhances practice management



What Can We Do – Rules to Live By

- Protect Yourself
- Allow Detection
- Preserve Evidence



Now the Good News!

- Detecting embezzlement is easier than many doctors (and consultants) realize
- Embezzlers must exhibit common “red flag” behaviors
- Behavioral clues unearth most embezzlement

Contact Info

pat@patlittle.com
 www.patlittle.com
 706.263.4450 (mobile)