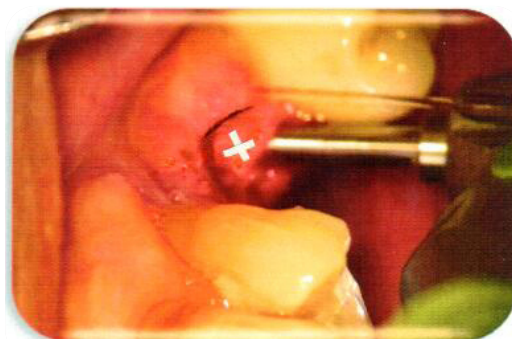

# ALVEOLAR RIDGE PRESERVATION USING THE BIOACTIVE HYDROPHILIC OSTEOGEN® BONE GRAFTING PLUG WITHOUT A MEMBRANE FOR TOOTH EXTRACTIONS BY DENTAL SCHOOL STUDIES FOR DOCTORS INFORMATION

Doctors: Please ask your patients if they are allergic to collagen. **\*Advise patients to avoid alcohol, mouthwash or chlorhexidine for two weeks as this has been shown to be toxic to fibroblasts and may retard healing and crestal bridging of soft tissue\*.**

## Fig. 1: Extraction and Debridement

Following anesthesia, extract tooth using standard atraumatic flapless protocol. **Thoroughly remove the granulation tissue and the entire pathologic periodontal ligament using the Implants Ltd Ultra Coarse Diamond Bur<sup>SM</sup>, see photo white X, removal of all infected ligament. Debride twice and flush socket with normal saline.**<sup>1-3</sup>



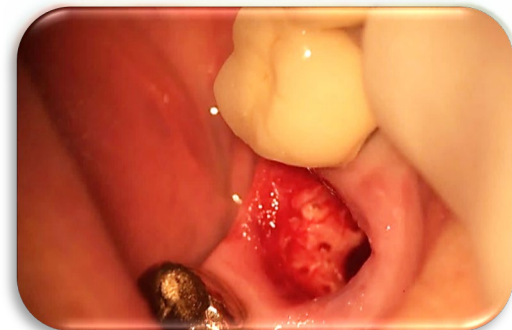See Video on UCD Bur at:

<https://www.impladentltd.com/product-p/bur-kit.htm>



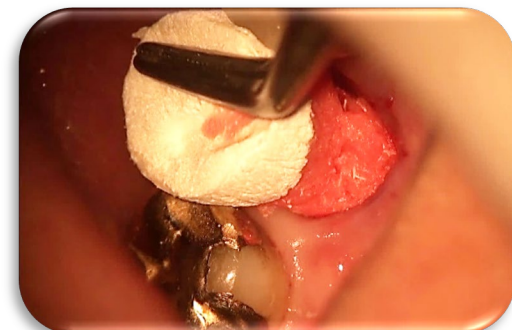
## Fig. 2: Generate Bleeding to Establish the RAP

Using the #6 carbide bur included in the UCD kit remove the **Lamina Dura** and make lingual or palatal holes in the lower half of the socket **where trabecular bone is available** to procure medullary blood containing osteoclast cells (220µm) and osteoblasts to trigger the Regional Acceleratory Phenomenon (RAP).<sup>4</sup> Profuse bleeding will be absorbed by the hydrophilic OsteoGen® Plug and will help prevent dry socket. **Do not hydrate the Plug prior to delivery.**<sup>5,6</sup>



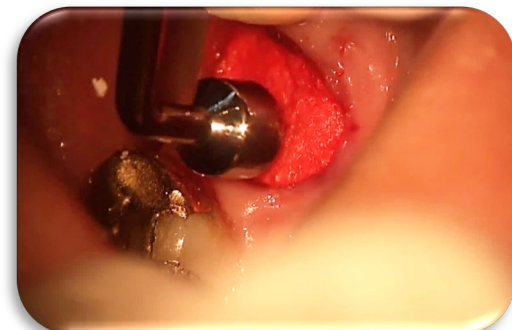
## Fig. 3: Delivery and Initial Plug Compression

Antibiotics with a low pH are not conducive to rapid bone formation. Aqueous **Metronidazole** is a preferred option that is closer to physiologic normal pH. **Following removal of the Lamina Dura, inject 2-3 drops mesiodistally at each side of the ridge crest as well as into the socket to kill bacteria and inhibit alveolar macrophage activity.**<sup>7-9</sup> Hold the OsteoGen® Plug with sterile tweezers, taper Plug apically and deliver into the socket. Compact the plug aggressively. The Plug should be large enough, initially with an excess of 3.0mm-5.0mm on average above occlusal plane, so that it can be compressed into and fill the entire socket to the **soft tissue superior level**. **Do not place Plug to the crestal bone height!**



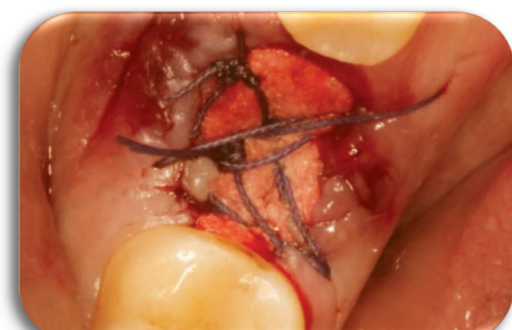## Fig. 4: Final Compression: "Making a Membrane"

Plug compression is achieved by **using a Plugger Instrument to align and compact the bone grafting crystals closer together creating a bioactive membrane barrier which controls migration of connective tissue.**<sup>10-12</sup> Must use more than one Plug for multiple roots. Fill and unite the Plug roots **superiorly at the root trunk to the level of the soft tissue crest**. Leave the top of the Plug intact so it can be compressed into the socket uniformly. No toothbrushing or waterpik and avoid alcohol, mouth wash or chlorhexidine for two weeks to yield rapid tissue healing crestally.



## Fig. 5: Suturing; Radiolucent to Radiopaque

Passively crisscross suture over Plug, **not through the Plug**. **Do not use Resorbable sutures**. Membrane Not Required. Soft tissue should bridge across in 9-14 days\*. The non-ceramic OsteoGen® crystals are a low-density graft material. Site will show radiolucent day of placement. Plug resorbs continuously in 3-5 months and longer and is replaced by host bone at a rate depending on the surgery and patient's age or metabolism. The site will become radiopaque and ready for implant placement. **OsteoGen® crystals may be used to reinforce the implant osteotomy prior to implant installation.**<sup>12-14</sup> After implant installation, place healing screw and additional crystals crestally to prevent downward migration of epithelium & achieve primary closure.<sup>10-12</sup>



Doctor please see videos online at [www.impladentltd.com/OsteoGen-Plugs-p/op.htm](http://www.impladentltd.com/OsteoGen-Plugs-p/op.htm)

## BIBLIOGRAPHY

1. Schlesinger C: Extraction with immediate placement and immediate temporization: the ultimate in patient satisfaction. *Implant Practice* 2015; 8(6):20-24
2. Kosinski T: Simple and predictable socket preservation techniques all dentists can implement regardless of extraction or grafting experience. *The Profitable Dentist* Summer 2016:46-50
3. Kosinski T: A Simple and cost-effective socket preservation technique. *Dentistry Today* 2016;35(4)
4. Frost HM: The Regional Acceleratory Phenomenon: a Review. *Henry Ford Hosp Med Journal* 1983; 31(1):3-9
5. Schlesinger C: Using OsteoGen® Strips to graft the gap around an implant: a case study. *Implant Practice* 2017; 10(3):25-30
6. Schlesinger C: A Novel approach grafting around implants. *Dentistry Today* 2017;36(12):50-54
7. Loesche WJ, Grossman N, Giordano J: Metronidazole in periodontitis (IV). The effect of patient compliance on treatment parameters. *J Clin Periodontol.* 1993;20:96-104.
8. Choukroun J, Simonpieri A, Del Corso M, Mazor Z, Sammartino G and Ehrenfest D: Controlling systematic perioperative anaerobic contamination during sinus-lift procedures by using Metronidazole: An innovative approach. *Implant Dentistry* 2008; 17(3):257-270.
9. Shakir, Lana & Javeed, Aqeel & Ashraf, Muhammad & Riaz, Amjad. (2011). Metronidazole and the immune system. *Die Pharmazie.* 66. 393-8. 10.1691/ph.2011.0790.
10. Spivak JM, Ricci JL, Blumenthal NC, Alexander H. A new canine model to evaluate the biological response of intramedullary bone to implant materials and surfaces. *J Biomed. Mater Research.* 1990; 24:1121-1149.
11. Ricci JL, Blumenthal NC, Spivak JM and Alexander H. Evaluation of a low-temperature calcium phosphate particulate implant material: Physical-chemical properties and in vivo bone response. *J Oral Maxillofacial Surgery.* 1992; 50: 969-978.
12. Valen M and Ganz SD. Part I: A Synthetic Bioactive Resorbable Graft (SBRG) for predictable implant reconstruction. *J Oral Implantology.* 2002; 28(4):167-177.
13. Valen M and Naman LJ: Dental Implant Orthopedics Basic Science Primer with Bone Grafting Techniques for Implant Success (Presented to the AO February 2016).
14. Valen M and Schulman A: Establishment of an implant selection protocol for predetermined success. *J Oral Implantol* 1990;16(3):166-171.