

Each of these six (6) factors is an independent "red flag" for sleep-disordered breathing.




Difficulty with exclusive nasal-breathing for 3+ minutes?

MOUTH BREATHING

NO

YES



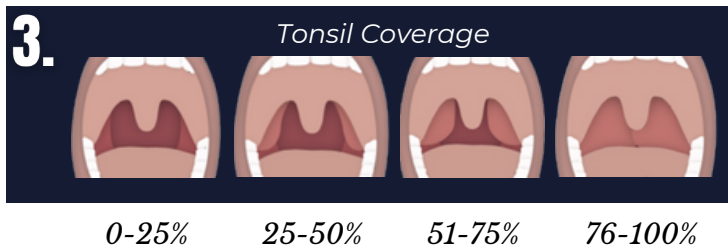
No Mentalis-Strain

Mentalis-Strain

MENTALIS STRAIN

NO

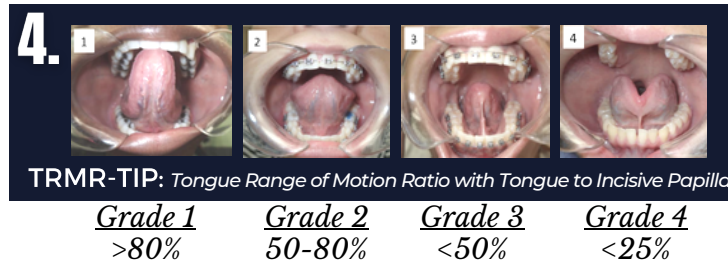
YES



TONSIL HYPERTROPHY

<50%

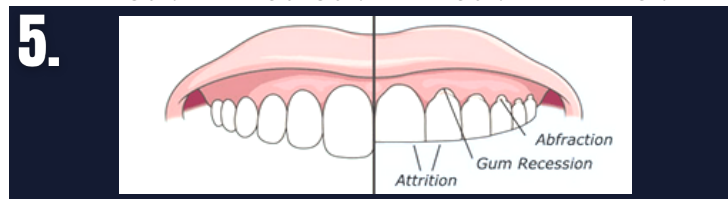
>50%



ANKYLOGLOSSIA

NOT RESTRICTED

RESTRICTED (GRADE 3-4)

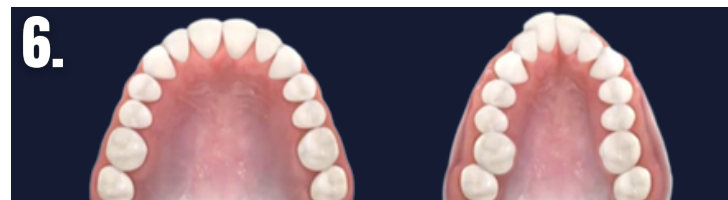

Are there visible signs of dental wear?

DENTAL WEAR

NO

YES



Signs of dental crowding, high arch, and/or narrow palate?

NARROW PALATE

NO

YES

GRADING SCALE

The score on the FAIREST-6 is equal to the sum of the number of exam findings present. Scores may range from 0 (none of the items are present) to 6 (all six of the concerning exam findings are present). **A score of two corresponds to mildly increased risk of sleep-disturbance; four indicates moderately increased risk; six indicates severely increased risk.**

Number of Red Flags
Risk of Sleep-Disturbance

Scoring Table for FAiREST 6

	0	1	2	3	4	5	6
	Normal		Mild		Moderate		Severe

FUNCTIONAL CLASSIFICATION OF ANKYLOGLOSSIA : *BASED ON TONGUE RANGE OF MOTION RATIO (TRMR)*

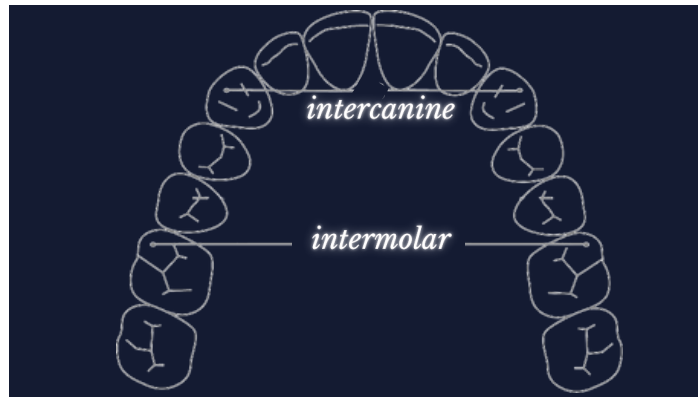
TRMR-TIP Assessment of Anterior Tongue Mobility Tongue to Incisive Papilla (TIP)

Grade 1: TRMR-TIP > 80% <i>Significantly Above Average</i>	Grade 2: TRMR-TIP 50-80% <i>Average</i>
Grade 3: TRMR-TIP < 50% <i>Below Average</i>	Grade 4: TRMR-TIP < 25% <i>Significantly Below Average</i>

TRMR-LPS Assessment of Posterior Tongue Mobility Lingual Palatal Suction (LPS)

Grade 1: TRMR-LPS > 60% <i>Significantly Above Average</i>	Grade 2: TRMR-LPS 30-60% <i>Average</i>
Grade 3: TRMR-LPS < 30% <i>Below Average</i>	Grade 4: TRMR-LPS < 5% or unable <i>Significantly Below Average</i>

MEASURING INTERCANINE & INTERMOLAR DISTANCE



Maxillary Intercanine Distance

a. > 37 mm (Wide) **b.** 31-37 mm (Neutral) **c.** < 31 mm (Narrow)

Maxillary Intermolar Distance
(Mesiobuccal Cusps)

a. > 52 mm (Wide) **b.** 46-52 mm (Neutral) **c.** < 46 mm (Narrow)

REFERENCES

1. Assessment of Nasal Breathing Using Lip Taping: A Simple and Effective Screening Tool.
Authors: Zaghi S, Peterson C, Shamtoob S, Brigitte Fung B, Kwok-Keung Ng D, Jagomagi T, Archambault N, O'Connor B, Winslow K, Peeran Z, Lano M, Murdock J, Valcu-Pinkerton S, Morrissey L.
2. Determinants of Sleep-Disordered Breathing During the Mixed Dentition: Development of a Functional Airway Evaluation Screening Tool (Fairest 6).
Authors: James Oh DDS, Soroush Zaghi MD, Cynthia Peterson PT, Clarice S Law DMD MS, Audrey J Yoon DDS MS.
3. Determinants of probable sleep bruxism in a pediatric mixed dentition population: a multivariate analysis of mouth vs. nasal breathing, tongue mobility, and tonsil size.
Authors: Oh J S, Zaghi S, Ghodousi N, Peterson C, Silva D, Lavigne G J, Yoon, A.
4. Assessment of posterior tongue mobility using lingual-palatal suction: progress toward a functional definition of ankyloglossia.
Authors: Zaghi S, Shamtoob S, Peterson C, Christianson L, Valcu-Pinkerton S, Peeran Z, Fung B, Kwok-Keung Ng D, Jagomagi T, Archambault N, O'Connor B, Winslow K, Lano M, Murdock J, Morrissey L, Yoon A.
5. Ankyloglossia as a risk factor for maxillary hypoplasia and soft palate elongation: A functional - morphological study.
Authors: A J Yoon, S Zaghi, S Ha, C S Law, C Guillemainault, S Y Liu.